



**CANADIAN OF BOARD
AESTHETIC MEDICINE**

Patient's name:

Date:

Step 1: Patient's main concern(s):

.....

Step 2: Glogau Classification of Photoaging

Group	Classification	Typical Age	Description	Skin Characteristics
I	Mild	28-35	No wrinkles	Early Photoaging: mild pigment changes, no keratosis, minimal wrinkles, minimal or no makeup
II	Moderate	35-50	Wrinkles in motion	Early to Moderate Photoaging: Early brown spots visible, keratosis palpable but not visible, parallel smile lines begin to appear, wears some foundation
III	Advanced	50-65	Wrinkles at rest	Advanced Photoaging: Obvious discolorations, visible capillaries (telangiectasias), visible keratosis, wears heavier foundation always
IV	Severe	60-75	Only wrinkles	Severe Photoaging: Yellow-gray skin color, prior skin malignancies, wrinkles throughout—no normal skin, cannot wear makeup because it cakes and cracks

What is the group of photoging?

Step 3: Aging assessment:
(Volume loss, sagging)

Forehead:


Temple:

Midface/cheeks:

Lips:

Jawline and lower face:

Chin:



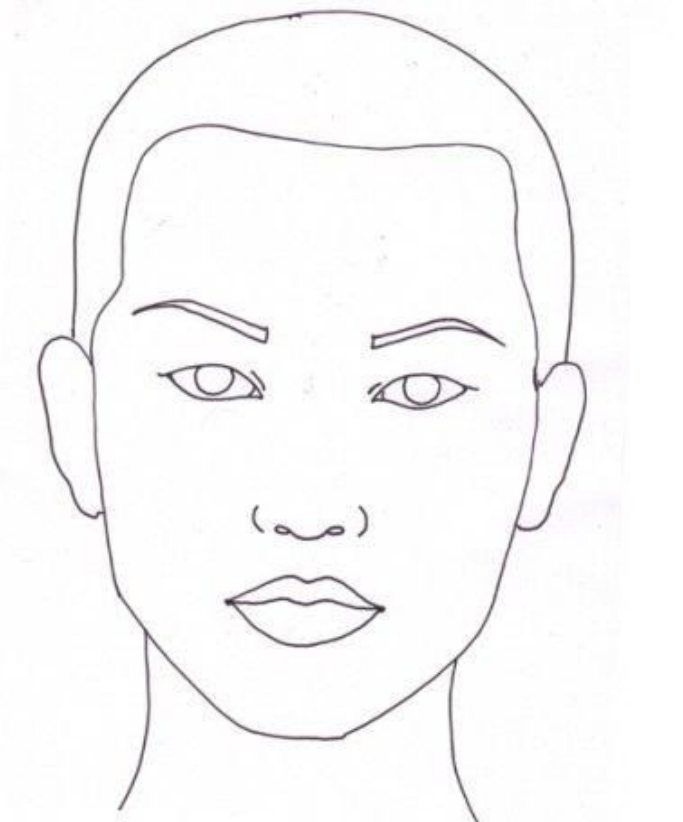
Step 4: Facial proportions/Augmentation:

Lips:

Nose:

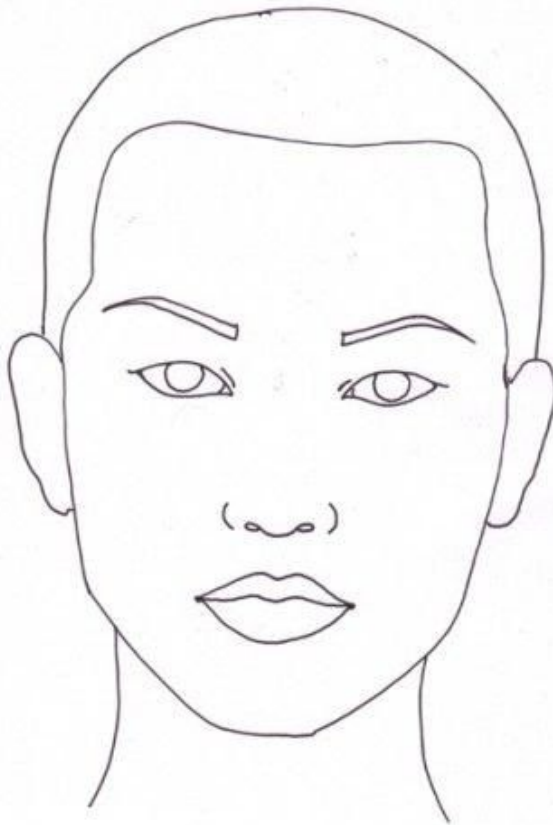
Chin:

Jawline:



Step 5: Treatment plan:

Neurotoxin:
Filler:
PRP:
Skin Boosters:
Skin Products:
Microneedle:
Laser:
Chemical Peel:
Sclerotherapy:



Student's name:

Instructor's name: